



DANBIO

April 2016

Nye reference billeder Atlas

Lene Bak
Overlæge
Radiologisk Afdeling
Muskuloskeletalt afsnit
Odense Universitetshospital

DANBIO

Radiographic evaluation of rheumatoid arthritis

Difficulty of standardized scoring by different readers



The creation of Reference Images

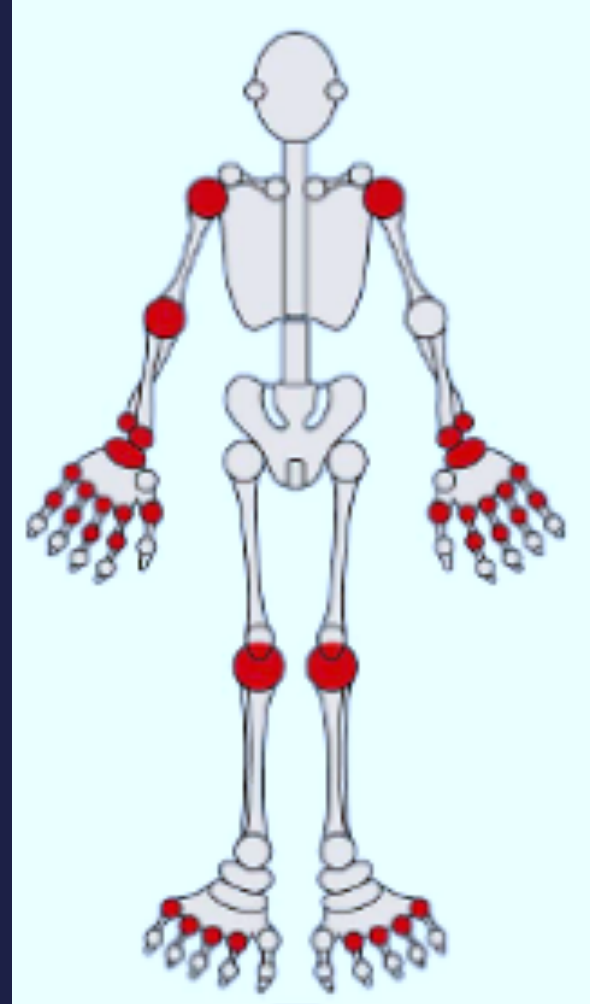
Atlas

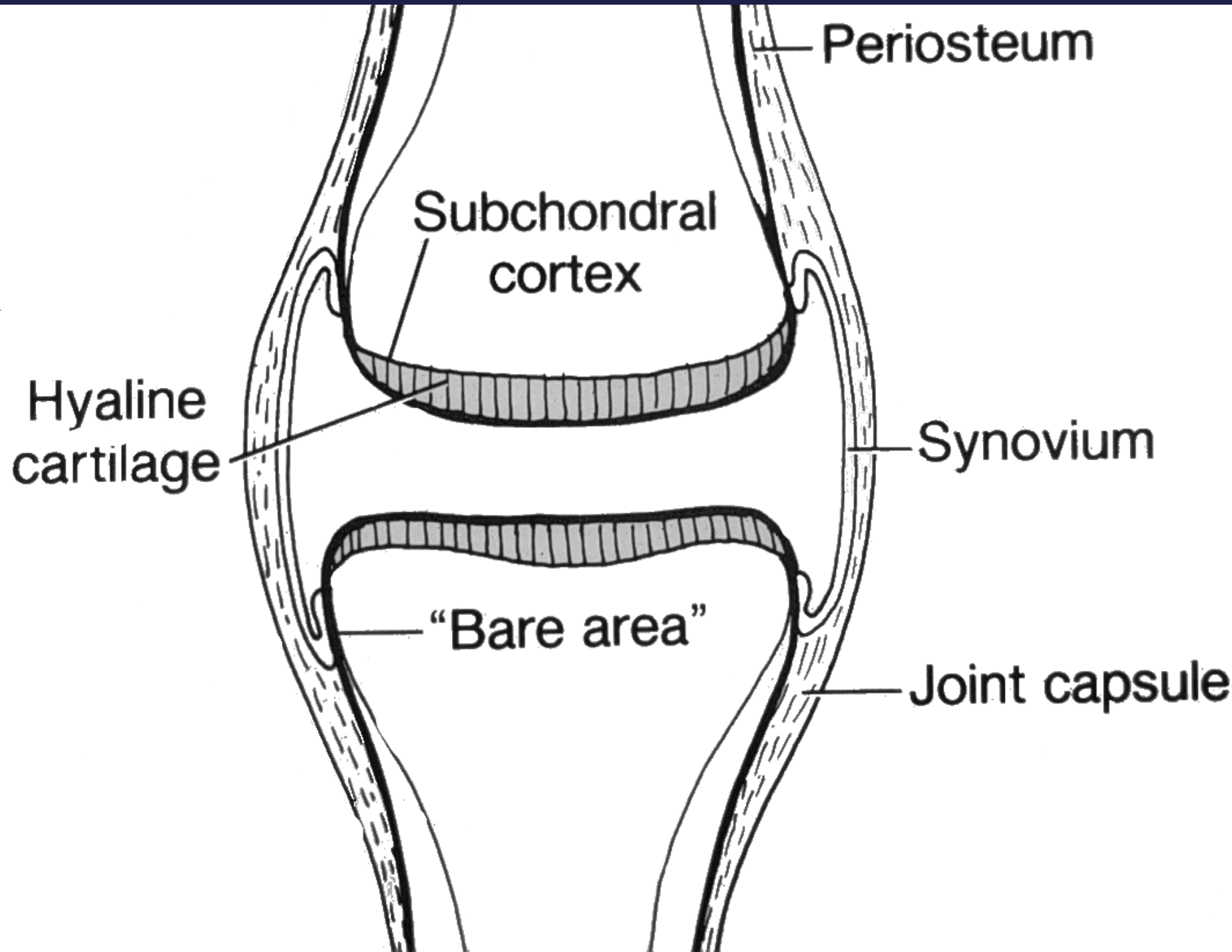
Radiographic evaluation of rheumatoid arthritis

- Best choice: Routinely standardized scoring in a Radiology Information System (RIS)
- DANBIO (Copy to RIS): figures in stead of text, comments possible

Rheumatoid arthritis

- Chronic inflammatory disorder
- Typically affects the small joints of hands and feet





Periosteum

Subchondral
cortex

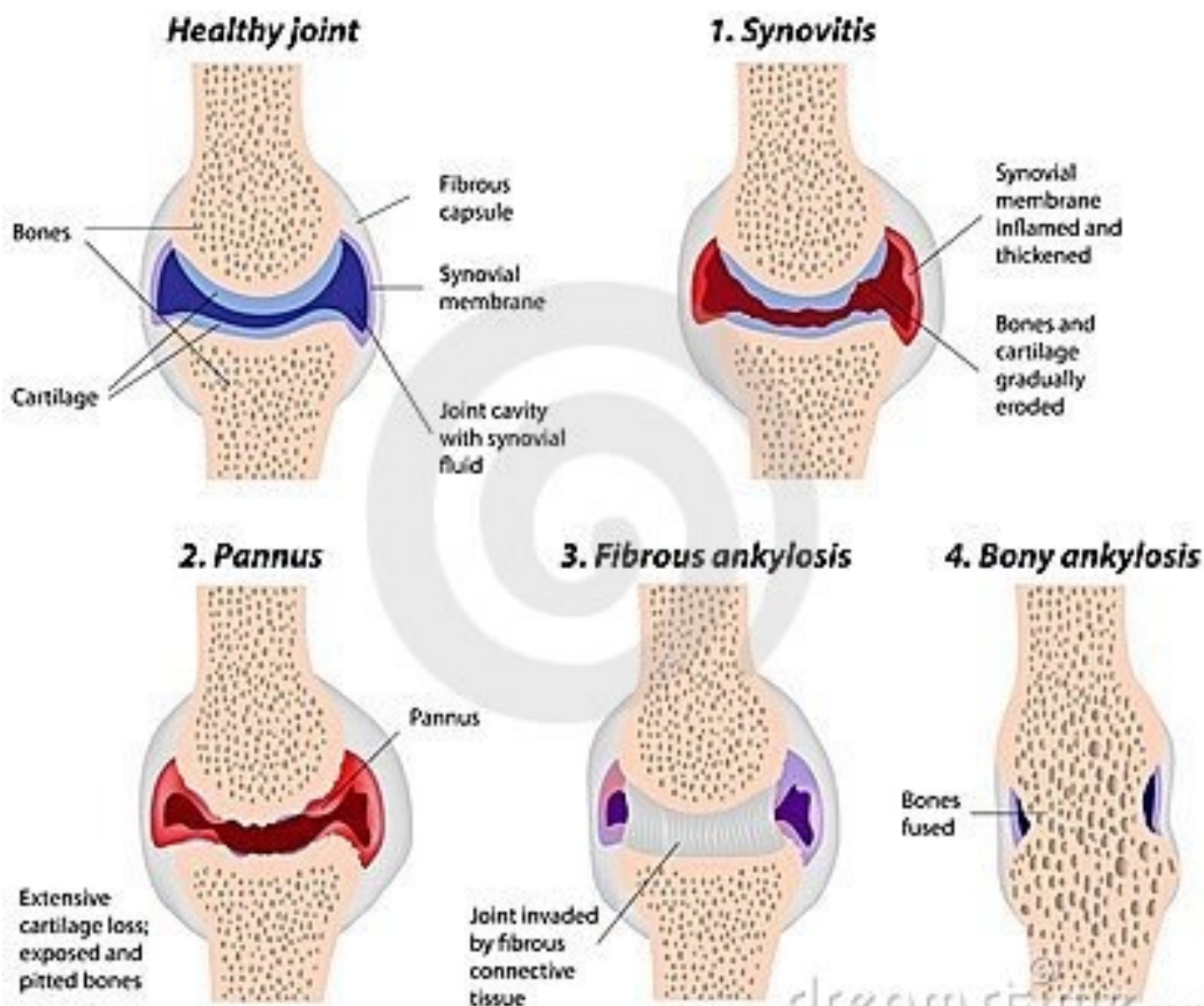
Hyaline
cartilage

Synovium

"Bare area"

Joint capsule

Stages of Rheumatoid Arthritis



Rheumatoid arthritis

Radiographs

Synovial inflammation leading to:

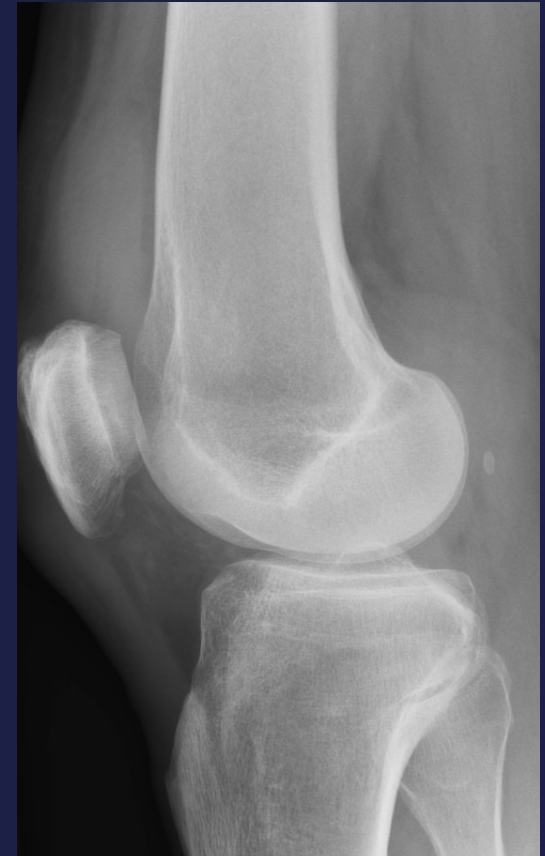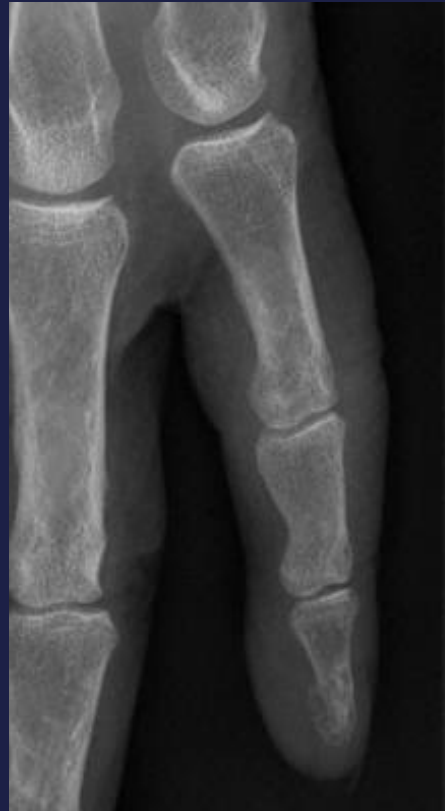- Soft tissue swelling
- Periarticular demineralisation
- Cartilage destruction → joint space narrowing
- Bone erosions

RHEUMATOID ARTHRITIS

Radiology

Soft tissue swelling

- Often the first sign
- Intraarticular effusion, displaced fat-pads

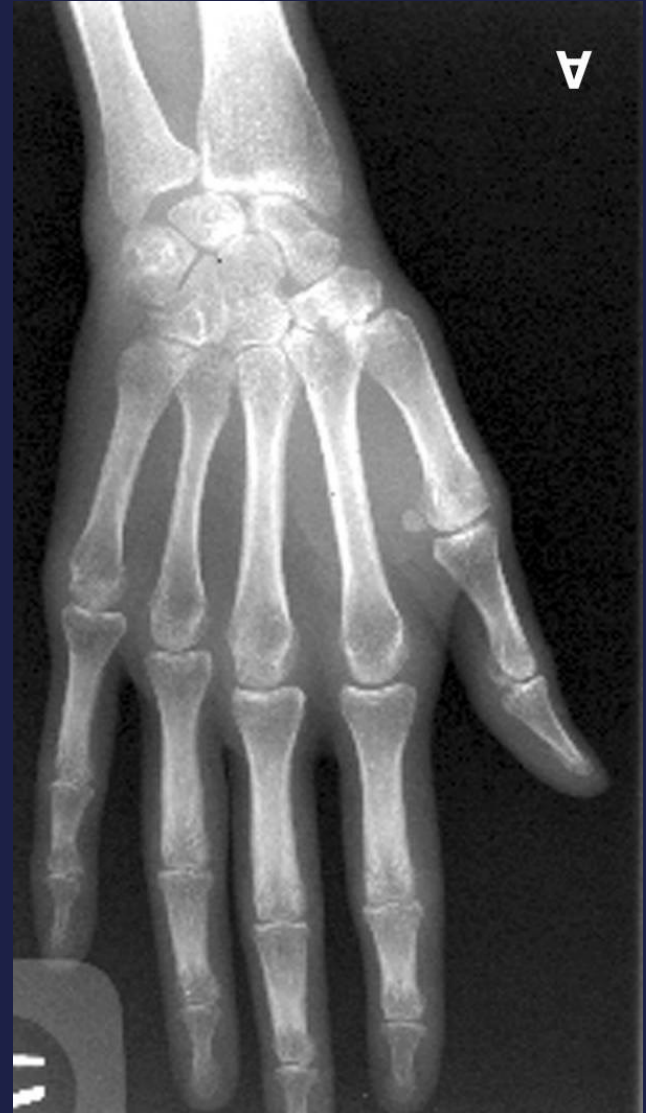

RHEUMATOID ARTHRITIS

Radiology

Periarticular demineralisation

Later general demineralisation

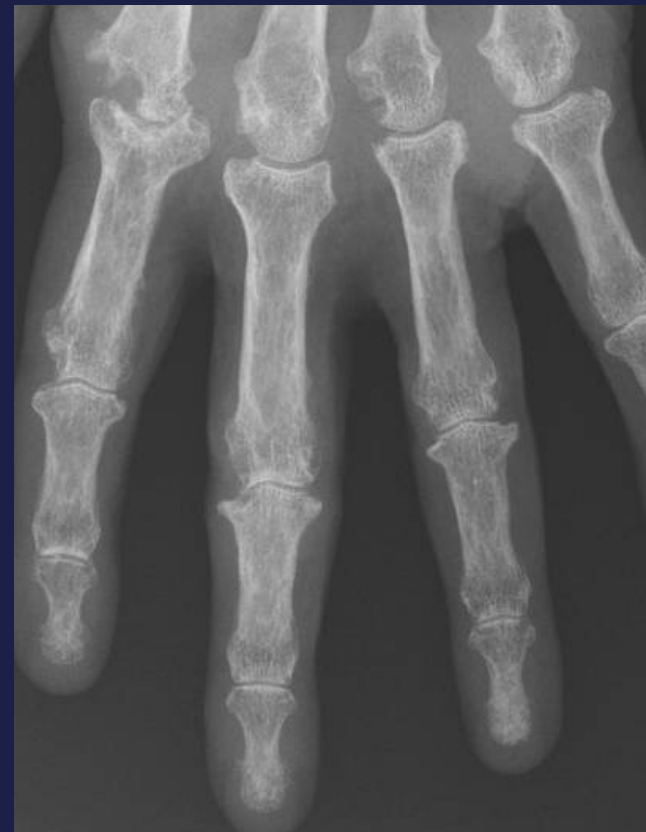


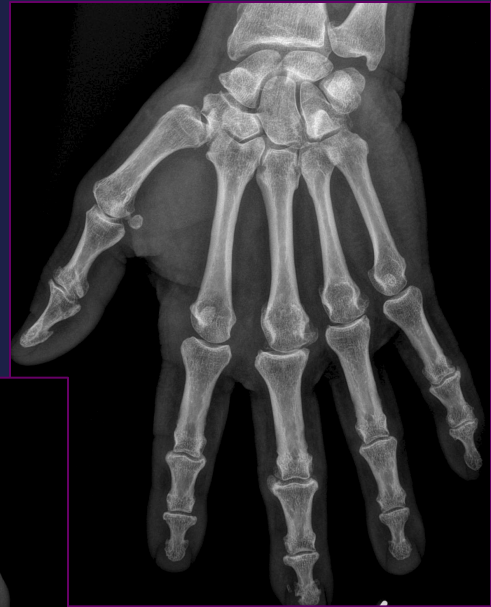
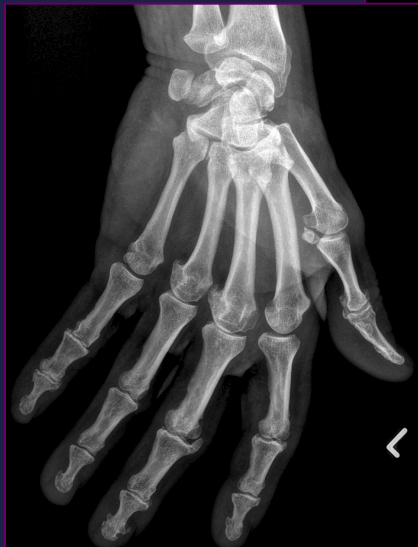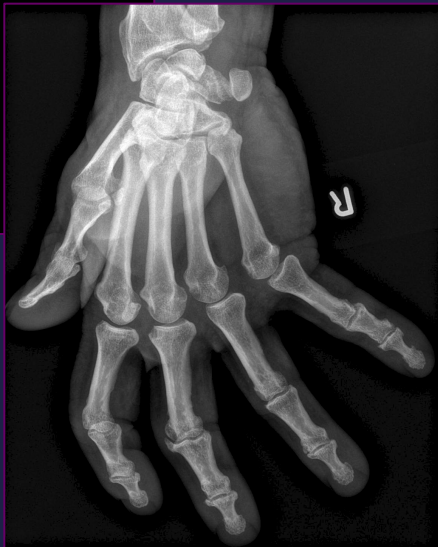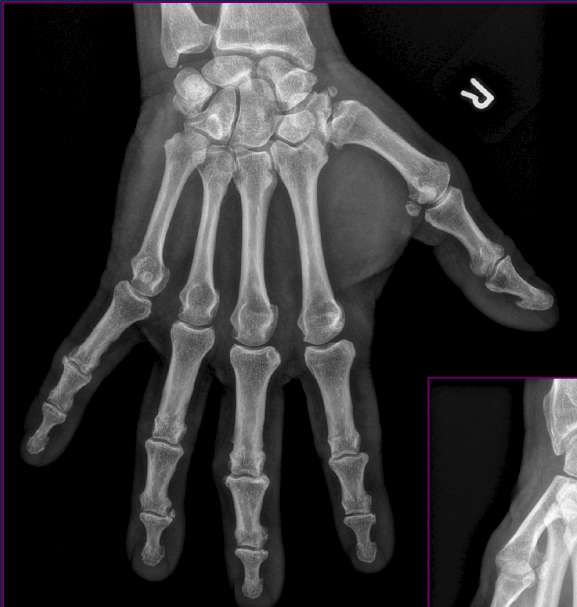RHEUMATOID ARTHRITIS

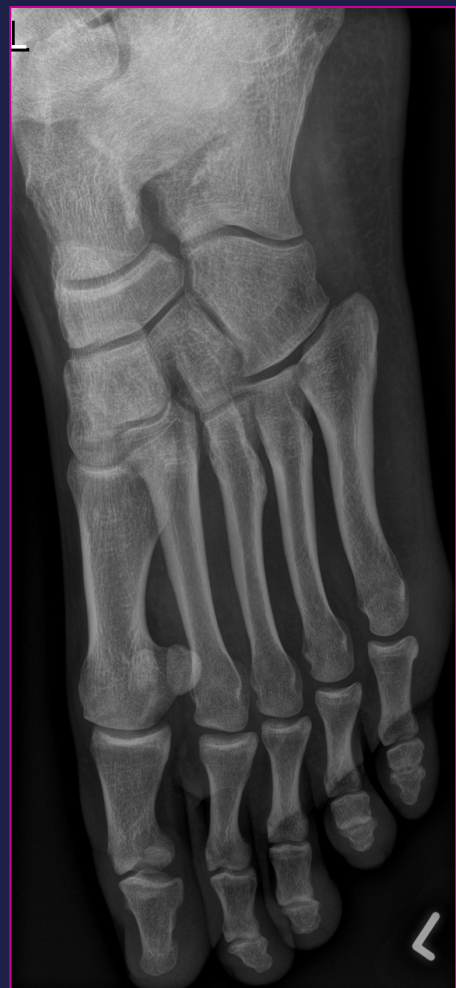
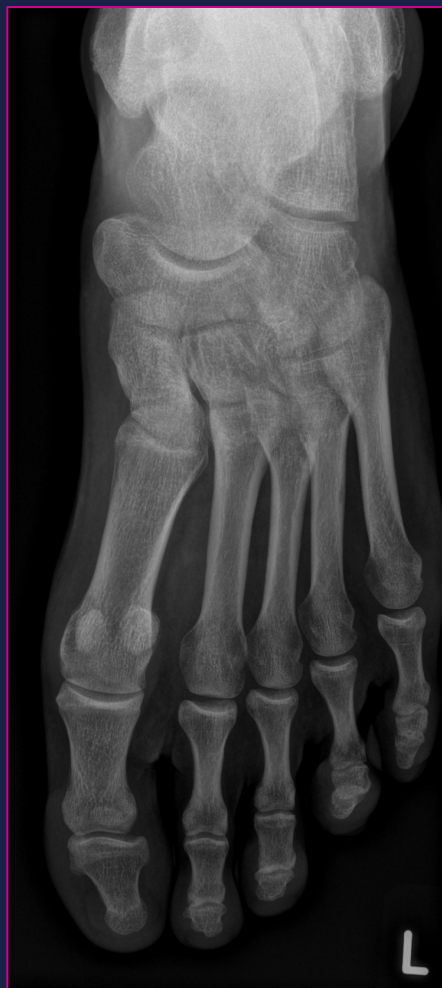
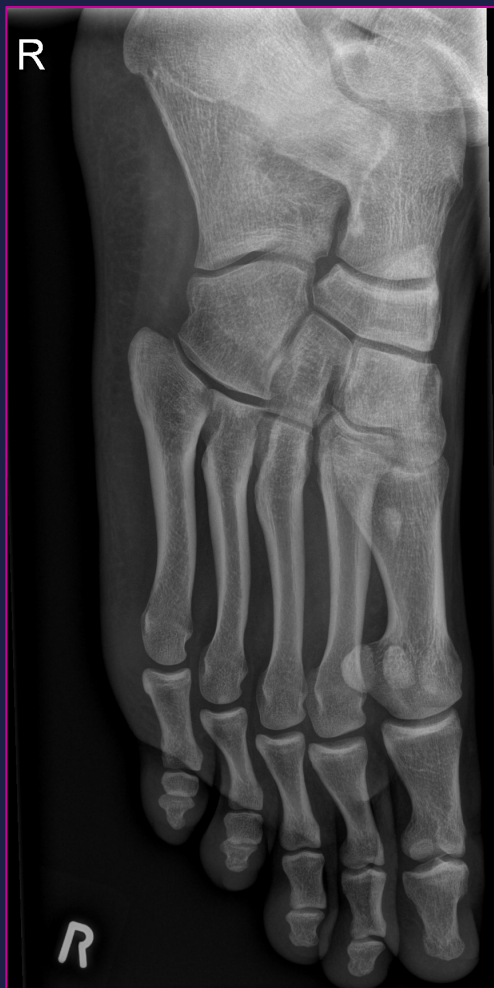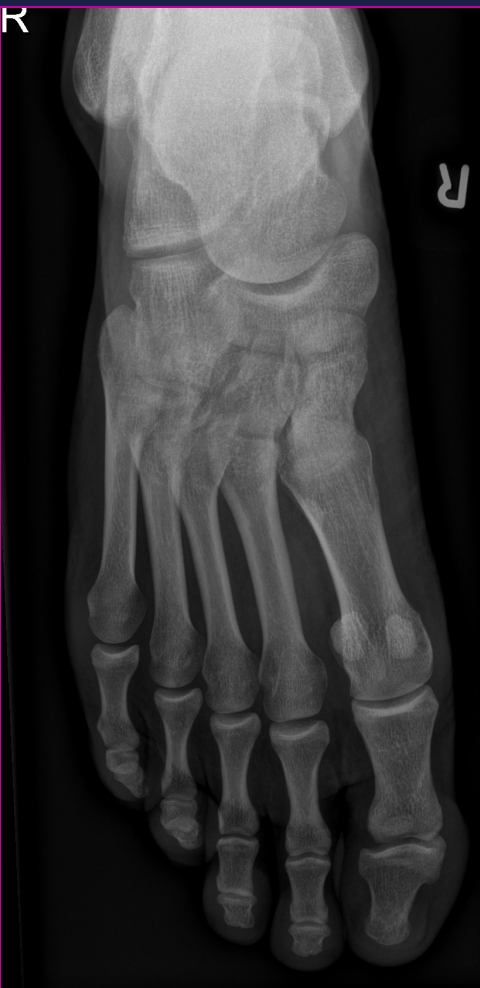Radiology

Joint space narrowing

Bone erosions

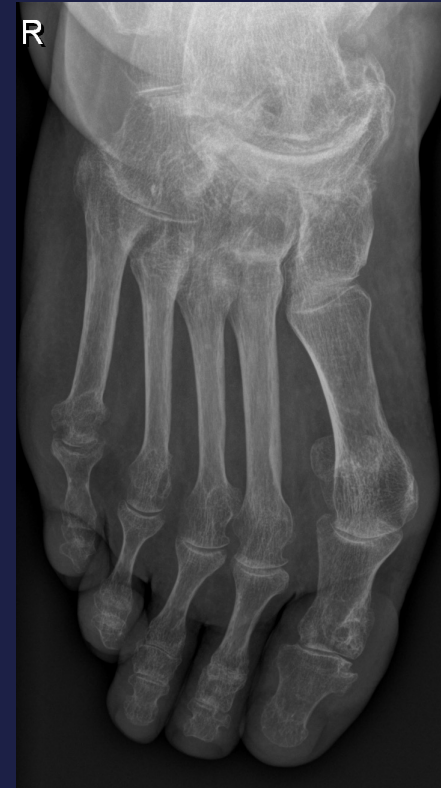
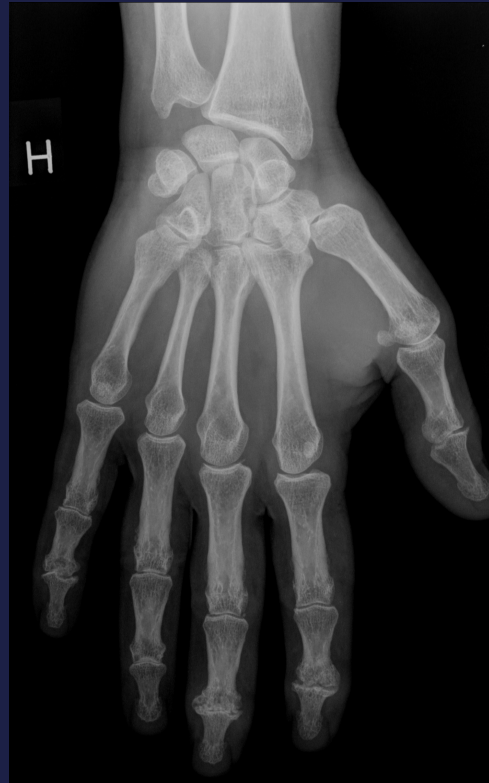




The Larsen Method

- Erosions
- Joint space

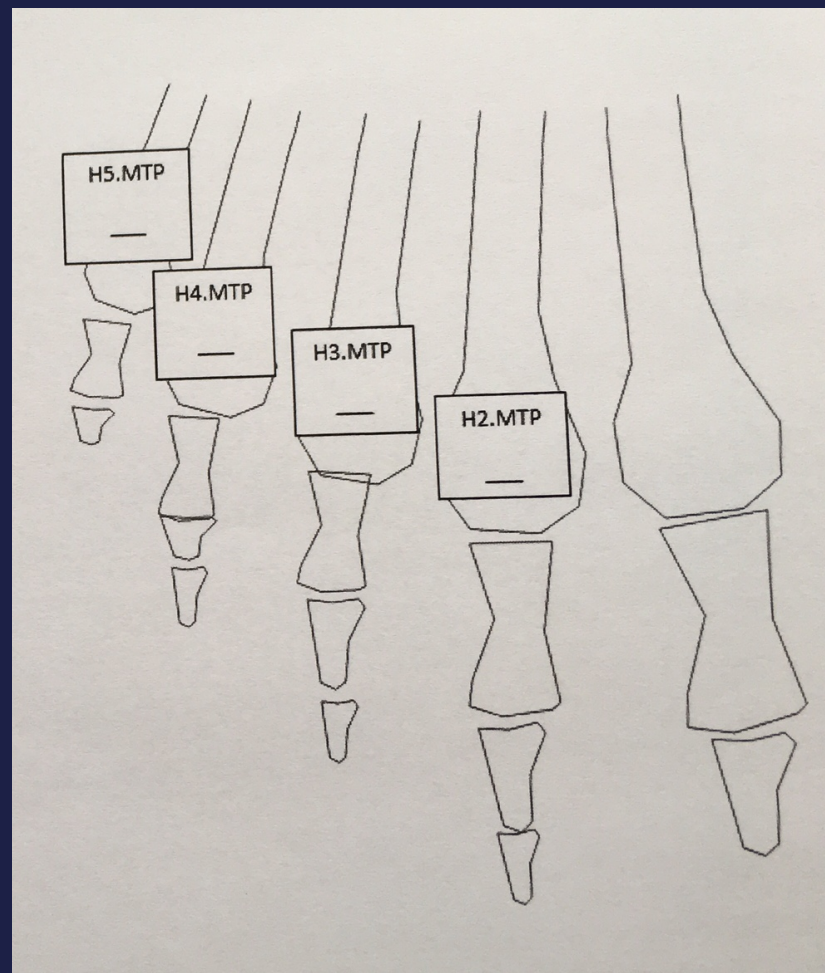
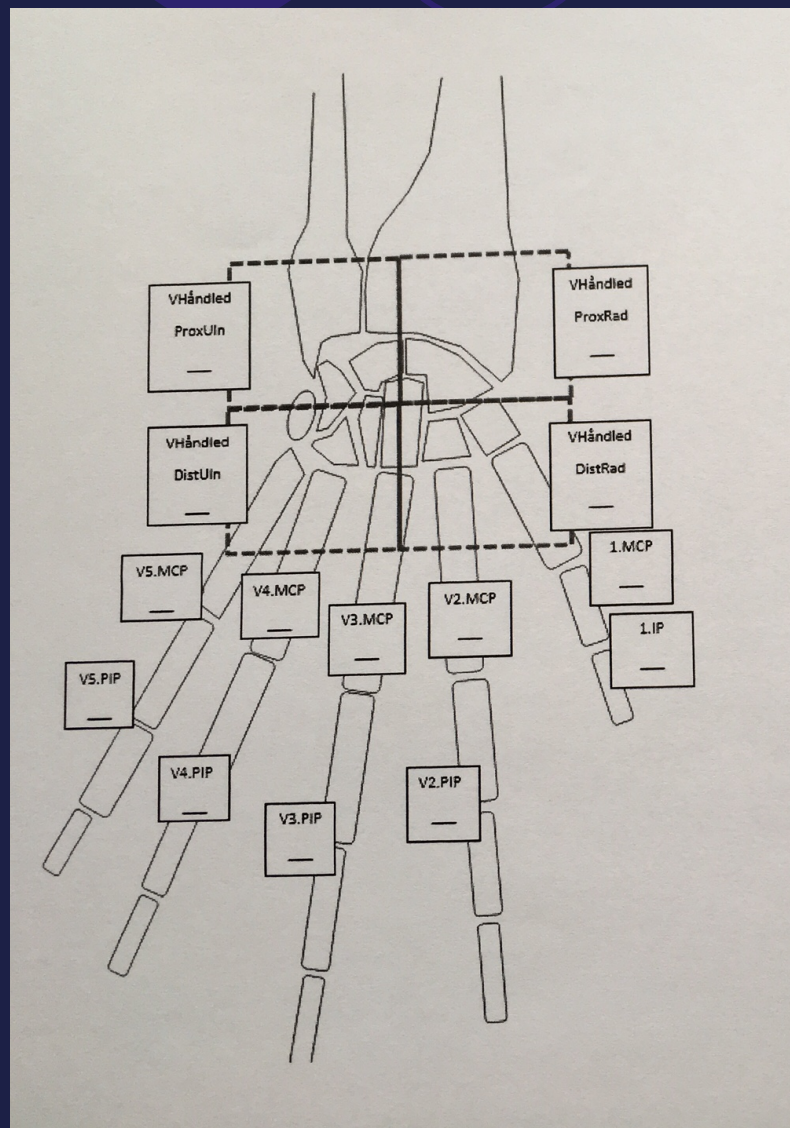


- Radiographs of wrists/hands and feet in frontal projection

The Larsen Method

- 0 = Normal
- 1 = Unspecific: soft tissue swelling, periarticular demineralisation, effusion
- 2 = One or several small erosions, jointspace narrowing
- 3 = Marked erosions (deeper), most of the bony outlines preserved
- 4 = Severe erosions, most of the original bony outlines are destroyed
- 5 = Mutilating changes, where the original bony outlines have been destroyed

The Larsen Method





The Larsen Method Atlas

- Patients with known rheumatoid arthritis



Grade 0 – Larsen score

Normal



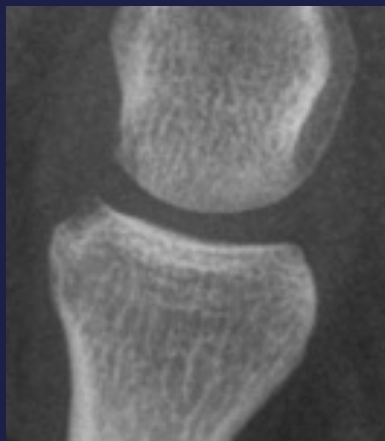
Grade 1- Larsen score

We do not score grade 1 -
unspecific

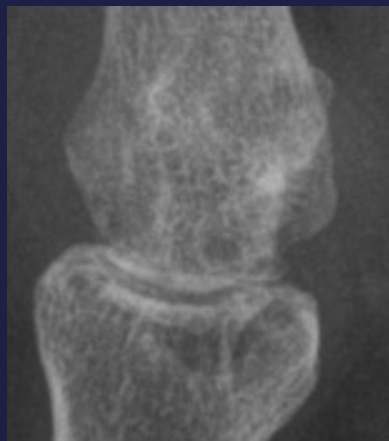
Juxtaarticular osteopenia
Joint effusion
Soft tissue swelling

MCP – Larsen score

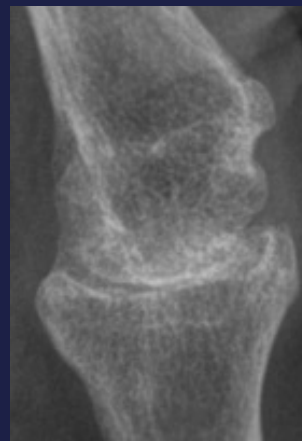
St. 2



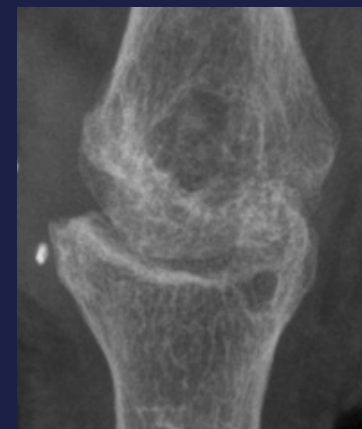
St. 3



St. 4

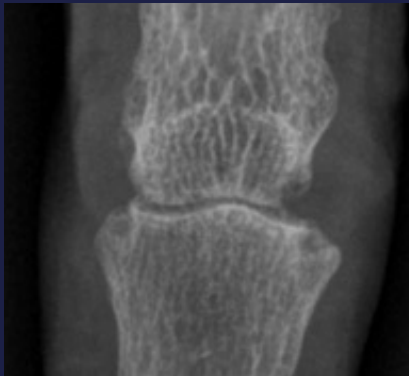

St. 5

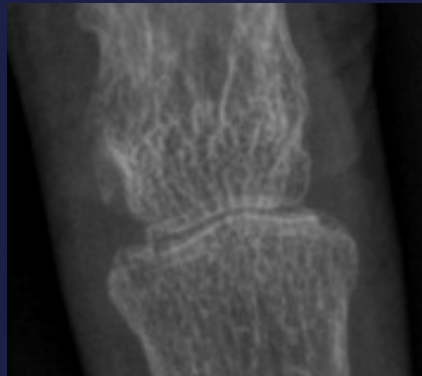

PIP- Larsen score

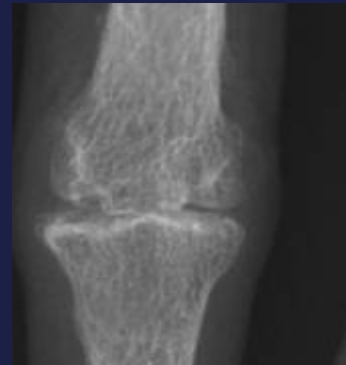
St. 2



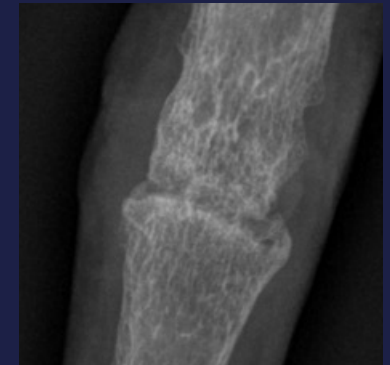St. 3



St. 4

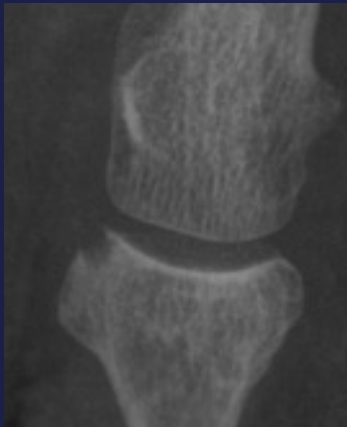


St. 5

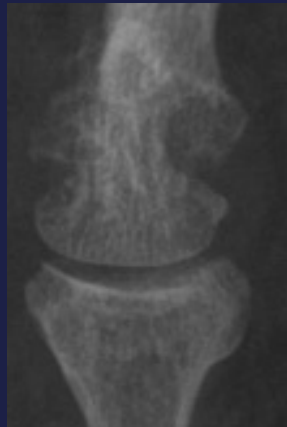

MTP- Larsen score

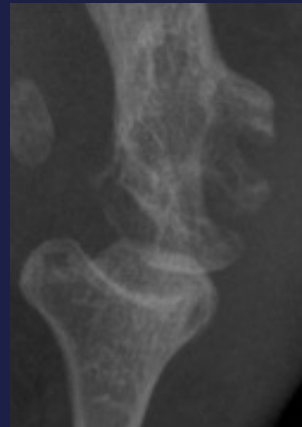
St. 2



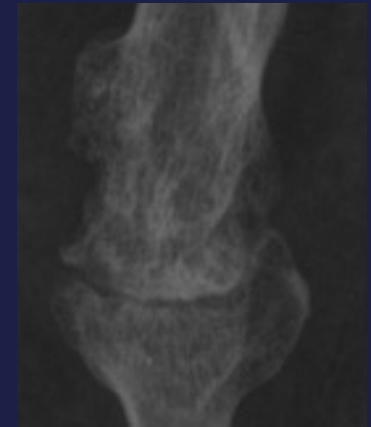
St. 3



St. 4



St. 5



Work in progress



Thanks